

HYPOTHESIS: CRANIAL BIOMECHANICS**The SBS Revisited - The Mechanics of Cranial Motion**

Andrew Cook MSc RCST, December 2004

Andrew Cook is a craniosacral practitioner working in Norwich, UK, with a background in engineering and computational fluid mechanics. **Contact Address** : Andrew Cook, Complementary Health Centre, 34 Exchange Street, NORWICH NR3 2JY United Kingdom.

Journal of Bodywork and Movement Therapies (2005), Vol 9 (3) July, pp 177-188 Online Publication DOI : 10.1016/j.jbmt.2004.12.002, available at <http://authors.elsevier.com/sd/article/S1360859205000069>

Abstract

Building on Sutherland's approach to sutures ("form follows function and function follows form") applied to the thicknesses – and hence flexibility – of cranial bones, a new model of cranial motion has evolved. This places the sphenobasilar synchondrosis (SBS) as a primarily compressive-decompressive joint. SBS hinging is seen as an illusory artefact created as tissue rotations around a stable SBS. This article suggests that the apparent motion of the SBS instead takes place by a change in shape of the anterior body of the sphenoid, and that this motion is accommodated by the superior orbital fissure. This new model can be used to derive cranial bone motion patterns directly from the assumption that the cranium changes its lateral diameter, and elegantly explains the well-known "four interlinked gears" description of the occiput - sphenoid - vomer/ethmoid train. The model does not require sutures to be patent or membranous, since it applies equally well to ossified suture relics.

A. Introduction

The aim of this paper is to explore osseous motion of the cranium from a biomechanical perspective. For the sake of simplicity, this has been done with as little reference as possible to driving mechanisms for the "Cranial Rhythmic Impulse" (CRI – also called the "Craniosacral Rhythm or CSR) – physiological or otherwise. It is also intended that no assumptions should be made regarding the driving force behind the CRI - there is still no model available for the CRI which agrees with both modern physiology and palpated phenomena. Consequently, the descriptions presented are a detailed clarification of Sutherland rather than a new model of cranial motion, and might be considered as a further round of "digging on" (Sutherland, 1998, p. 167). Cranial bone, periosteum, dura and their enclosed fluids, neural tissues and vascular structures are part of a dynamic continuum of varying stiffness and elasticity. Their total motion can theoretically be analysed and described by just examining the bony structures. This is simply an extension of the study of skeletal detail to understand the musculoskeletal system. Therefore, again for reasons of simplicity, the following thesis contains limited reference to the dura, falx and tentorium.

Historical Context

It is over 80 years since Sutherland (1998) discovered the motion of cranial bones by inspection of a disarticulated skull and application of the principle of "*form follows function and function follows form*" to sutures. Sutherland's original brilliant insight that sutures are lines of relative ease of motion in the bony skull eventually evolved from a concept centred on bones to a far more complex, holistic and subtle understanding of the bony, fascial and fluid nature of cranial motion, eventually encompassing the entire human body. The original concepts of sphenobasilar synchondrosis (SBS) motion continue to be central to basic techniques in Craniosacral Therapy and Cranial Osteopathy

(CST/CO), as does the concept of non-bony sutures, to accommodate this model of cranial motion.

B. Does the cranium move?

The *a priori* basis for this paper is the palpatory experience shared by craniosacral therapists and cranial osteopaths that the cranium naturally moves. Palpated cranial motion (the CRI) is usually rhythmic, moving in a recurring "Flexion-Extension" (F-E) cycle, with the "expansive" phase having been historically (Sutherland, 1998) described as "Flexion", and the "contractive" phase as "Extension". Flexion is most simply perceived as a lateral widening and an anterior-posterior (A-P) foreshortening of the skull. This motion is most simply described as a *change in shape*, with the cranium becoming more "round" (spherical) during Flexion¹.

Sutures as evidence of motion

The mere fact that sutures exist at all – even as relics – could be considered evidence of cranial motion. In the neonate, the cranium is still soft, and consists of thin membranous material surrounding slightly harder ossification centres. The anterior fontanelle (bregma in adults) is so thin that the cardiac pulse is visible. This soft structure of the baby skull is a result of the need to negotiate the birth canal. Bone growth ideally matches the volume requirements of the brain as the centres of ossification gradually expand outwards and meet at the sutures. Some sutures, such as those between the segments of the temporals and between the occipital squama, disappear entirely in all adults during this ossification process. With adulthood the

¹ A capitalised "*Flexion*" is used to refer to motion, as in Flexion-Extension (F-E), with "*flexing*" or "*flexes*" describing the bendability of cranial bones. Only the Flexion phase of motion is described in detail because the extension phase is simply the reverse motion. All descriptions of Flexion begin at the peak of Extension. All descriptions are of adult anatomy/physiology unless otherwise stated.

bones harden, but still retain flexibility by virtue of their thinness and from the fact that they are alive, containing blood vessels and nerves. The manual deformability of the ribs can be used as an analogue to give some impression of the magnitude of internal or external forces necessary to create palpable cranial motion.

As bony plates expand towards each other, the intervening sutures shrink back to relic lines of complex shape, persisting for some time as periosteal/cartilaginous tissue (Upledger & Vredevoogd, 1983, Appendix A). Hartman and Norton (2002) cite fresh-tissue autopsy and MRI (living tissue) evidence that the SBS fuses in most adults before the age of 19. Similarly, most vault sutures appear to ossify before the age of 30 in most adults. However, the evidence remains contradictory. Sutures retain more viscous mobility than surrounding bones (Steenvoorden et al., 1990). Singer (1953) found that human sutures may remain open even beyond the age of 60, but most histological and laboratory evidence of retained sutural mobility comes from *in vivo* and dissected animal studies rather than human studies. Byron et al. (2004) studied the effects of temporalis muscle strength on the morphology of the sagittal suture, concluding that "*cranial suture connective tissue locally adapts to functional demands of the biomechanical suture environment.*" Ogle et al. (2004) showed that mechanical motion delays the ossification of sutures.

The presence of Wormian bones (small ossicles within cranial suture lines) is hard to explain unless motion has to take place around a suture regardless of the original locations of ossification sites or neonatal sutural lines. Conversely, the fact that most adult sutures are ossified relics indicates that even if the presence of the suture is important to accommodate motion, its morphology is less so. Unlike armour, most cranial bones do not overlap but rather must be strongly abutted to provide adequate protection for the brain whilst not damaging the dura. Therefore, motion is enhanced along sutural lines but the sutures are nevertheless quite tight, consisting of extensions to the periosteum (Upledger & Vredevoogd, 1983). They cannot open significantly or slide over each other; they can only provide some increased local bendability and flexibility. The great majority of sutures have interlinking projections and indentations that mechanically prevent sliding or shearing and assist the absorption of impact forces (Jaslow, 1990).

Important atypical sutures

There are two very important exceptions to the above description of sutures. Firstly, the superior orbital fissure lying between the greater and lesser wings of the sphenoid bone is special in that it remains open, being an exposed dural surface 1 or 2 mm wide and 15 to 20 mm long. Secondly, the sutures around the squama of the temporal bone possess some of the qualities of overlapping armour. The way subdural arteries (visible as impressions on the inner surface of the parietal) avoid the anterior section of the temporal squama suggests there is a relatively large physical motion along this line. I have no idea how much this *potential* sliding overlap is reflected histologically.

Recognition of cranial motion

The CRI is not recognized in English-language medical texts, since there is no record of intracranial pressure (ICP) changes in the bandwidth of 5-12 cycles/min (Davson & Segal, 1996); however, some neurosurgeons have noted a similar dural *motion* whilst carrying out operations (Upledger, 1995). Recent osteopathic studies have related the CRI to Traube-Meyer-Hering (TMH) waves (Nelson et al., 2001; Sergueef et al., 2002). CST/CO laboratory measurements (Upledger, 1995) and common palpatory experiences suggest that particularly mobile skulls change by up to 2 mm in lateral diameter during the CRI (see Adams et al., 1992, for a study of cranial motion in cats). Moskalenko et al. (1999) have measured cyclic changes in cranial diameter up to 1mm with frequencies between 6 and 14 cycles/minute.

C. Deceptive simplifications

Cranial textbooks (e.g., Magoun, 1951) place a lot of emphasis on sutural motion, providing highly sophisticated and exhaustive descriptions. However, they do not *fully* include bone flexibility in their models of cranial motion. This is for good reason. Cranial bones are complex in shape, in sutural morphology and in mobile relationship to their neighbours. The whole cranium moves as a complete and continuous unit/process along with the membranes and fluids that surround it. The total pattern of motion is complex, and is not easy to visualise or describe without isolating each bone or pair of bones. Regardless of whether the textbook authors intended this or not, one result of isolating structures, emphasizing the sutures, and the use of jargon suggestive of mechanical hinging is that the impression *subliminally* conveyed is one of a relatively rigid bone that *only* moves at its boundaries.

The concept of an "axis of rotation" is also found in cranial textbook descriptions, again subtly pushing towards an instinctive conceptual model that assumes rigidity. This can be seen in the recent paper by Oleski et al. (2002). This groundbreaking study of cranial motion using x-rays employed the lesser pterygoid wings of the sphenoid as a marker for the sphenoidal SBS angle. In doing so, it missed the point that the anterior sphenoidal body is composed of flexible bones that may move independently of the SBS. I do not believe that rigidity was part of the authors' *conscious* conceptual model, but rather that the subliminal implications of the commonly used "axis of rotation" jargon were not fully recognised.

Furthermore, the fact that a four-gear train (e.g., Milne, 1995; Sills, 2002) is useful as a conceptual model for memorising the relative motions of the occiput, sphenoid, vomer and ethmoid also provides a mental smokescreen. The degree of accuracy of the motion description has removed attention from the actual processes behind this complex relative motion, and there are so far no published descriptions of cranial bone motion that adequately describe *how* or *why* this pseudo-gear motion comes about.

Palpatory Paradoxes

There are two clearly palpable motions of the CRI that can be experienced as a paradox if the cranial bones are considered to be rigid, with most motion occurring along sutures:

- a) The fact that the cranium becomes more spherical on Flexion. To a palpator with no preconceptions as to what the cranial structures may be doing, this takes place by means of a lateral expansion of the parietals and superior temporal squama, and a slight anterior-posterior foreshortening of the occiput-frontal axis. Although the mechanism driving it is still under debate, the existence of this change in dimension has been well demonstrated in several laboratory experiments cited by Upledger (1983, 1995) and is easily palpated by anyone who cares to sit quietly holding a head in their hands.
- b) Although Sutherland emphasised the complexity and holistic nature of cranial motion, "Sutherland's SBS patterns" are a simplified description of cranial motion, treating the SBS as a universal joint. As described in this simplified model, the apparent motion of the sphenoid relative to the occiput is based on palpation of the greater wings of the sphenoid as they move relative to the occipital squama. During Flexion the sphenoid body and occipital squama are apparently separating in an A-P direction as a hinging motion takes place around their medial connection (the SBS).

If the sphenoid and occiput are truly moving as two rigid bodies around the hinge of the SBS, (b) would lead to a lengthening of the cranium, while (a) experientially demonstrates a foreshortening of the cranium.

D. Adding Bone Flexibility

Milne (1995) points out the amazing flexibility and aliveness of the cranial bones. His description of the ethmoid as being like "*the tiny head of a bird's skeleton, such as you might find under a bush after a hard winter*" conveys both an evocative and accurate image of delicate flexibility. Anyone who handles a real or high quality moulded disarticulated skull can also experience this flexibility to some degree. Even so, in the "real" demonstration skull, despite the obvious flexibility of this dead material, the delicate bones have calcified and become hard far beyond their state in a living body.

It is proposed that the cranium behaves somewhat as if constructed of cardboard, with the sutures acting as pre-folded lines or perforations. The cardboard flexes, and the perforations facilitate that flexing in a manner appropriate to the stiffness of the cardboard. In this case, it does not matter whether the sutures are ossified relics or soft periosteum – they are lines of relative ease of bending in a semi-rigid structure. Any visible relic suture – even if ossified – remains a line of diminished rigidity, and so also remains a preferred site for any flexing motion to occur, as described by Jaslow (1990).

The superior 70% of the metopic suture usually ossifies to the extent that it is invisible in most adult skulls; hence, it does not retain its ease of flexing. If this were the case for the metopic suture, it would presumably be the case for all sutures unless there were some biological requirement for them to remain slightly weaker than the surrounding bony plates. Conversely, if cranial bones were inflexible, sutures would have to be as extensive as in a neonate to allow motion; otherwise, the complex curved shapes would simply lock against each other.

Analysing sutures

The function of the sutures in the motion of the cranial vault and most of the base can be readily seen by inspecting sutural morphology, as described in Magoun (1951). For example, the interdigitations of the coronal suture allow a limited relative motion to take place between the frontal and parietal bones. These interdigitations overlap in different ways along the suture. Starting at the bregma, the parietals are overlapped by the frontal. Approximately 30 mm laterally from the bregma, this overlap reverses, and the frontal is overlapped by the parietals. It is well recognised (e.g., Magoun, 1951; Milne, 1995) that the coronal dome of the parietals moves in such a way as to flatten more than the dome of the frontal, and this suture allows this relative difference in flexing to take place. In fact, the parietals are joined medially by the sagittal suture, which acts as a hinge line, causing a flattening of the apex of the skull. This is demonstrated in Milne (1995, Vol. 2, p. 135).

However, an unbiased analysis of the morphology of the SBS does *not* yield an impression of motion other than possibly compression and decompression. The osseous SBS is a flat surface about 1.5 cm² in surface area. The two surfaces of the SBS are embedded in each other by short, sharp, wedge-like protrusions that cover the entire face of the SBS. The visible evidence suggests a highly stable "design" that is resistant to bending, rotation and shear forces. This is somewhat at odds with descriptions of the SBS contained in cranial textbooks, which usually consider it to be a location of substantial motion in the cranial base. A set of release techniques for SBS motion patterns (e.g., Upledger 1983, 1987; Milne, 1995) is central to basic cranial practice (CSTA, 2002). These techniques are designed to release what are often referred to as the "Sutherland Lesions", referred to henceforth as "SBS Lesion Techniques" (SBSLTs).

E. An analysis of cranial mechanics

This paper is not long enough to analyse cranial mechanics in anything remotely comparable to the kind of detail achieved by Magoun (1951). With the exception of a few simplified examples (such as the coronal suture description above), sutures will be described in generic terms, and the reader is referred to more authoritative texts (Magoun, 1951; Upledger & Vredevoogd, 1983; Upledger, 1987; Milne, 1995; Sills, 2002, 2004). Similarly, cranial bones flex in a highly complex pattern of motion, so only a brief description of these bones is possible due to space restrictions. Instead, the reader is encouraged to play (carefully)

with a disarticulated skull – of either real bone or flexible plastic – to confirm the descriptions of motion given here and perhaps add to them. Based on common materials engineering principles, it is proposed that the flexibility of living bone can be qualitatively experienced by flexing disarticulated bone or a plastic moulded skull. Therefore, although greater force is required to bend these analogues than to bend a living skull, *wherever the osseous thicknesses are well preserved*, so also is the qualitative stress-flex response.

It is important to recognise the total synergy between the amplitude of the CRI; the cranial bone thickness; the internal stress imposed on bones due to compression, shear and rotation; sutural morphology; the location of cranial membranes (the tentorium and falx); and tensile forces imposed by membranes and interlocked bones. Each one of these factors is dependent on all other factors. Furthermore, all this motion and transfer of tension and compression happens within the context of the bony skull functioning as a means of protection for the brain.

The main assumption in this analysis is that biological systems inherently self-optimize. From a mechanical perspective, this means that the body reaches a compromise between weight, strength and mobility, and that compromise is expressed in each individual structural component. This is in fact a re-wording of Sill's aphorism, "*form follows function and function follows form*".

Putting this into practice, animals needing a more rigid frontal bone have a partially ossified anterior falx. If no motion were necessary, far more internal ribbing would be possible, and the membranous tentorium and falx would possibly ossify like the parietals (which are membranous in origin), producing a cranium even more reminiscent of a walnut. The bony design of the cranium is also related to ICP. The *cranial* ICP of somebody standing is less than atmospheric, with "neutral" ICP occurring around the level of T1 (Davson & Segal, 1996), so the skull has to resist a compressive force. When somebody is lying down or is upside down, ICP exceeds atmospheric, and the cranium has to contain an expansive fluid force. Other less symmetrical stress-induced deformations also have to be accommodated due to factors such as lying with the head on a surface, impacts, forces exerted by muscles such as temporalis or sternocleidomastoid, and the weight of the cranium on the condyles. These may be quite dynamic, and may include compression, torsion and shear. All this day-to-day motion and variation in stress/strain patterns demands either rigidity (which is difficult to achieve in a biological structure) or built-in compliance.

Tensegrity structures

Tensegrity principles (Ingber, 1998) state that bones transmit compressive forces, whereas membranes transmit tensile forces; also, that the compressive and tensile components have a synergistic relationship. Hence, the bony skull accommodates external pressures and internal compressive stresses by "bottoming out" on its sutural surfaces. Likewise, the cranial falx and tentorium transmit tensile forces laterally and A-P; the cranial dura accommodates internal pressures in a manner reminiscent of

a balloon, placing an area-equalised expansive force on its surrounding and closely attached bony protective layer.

Rules of motion

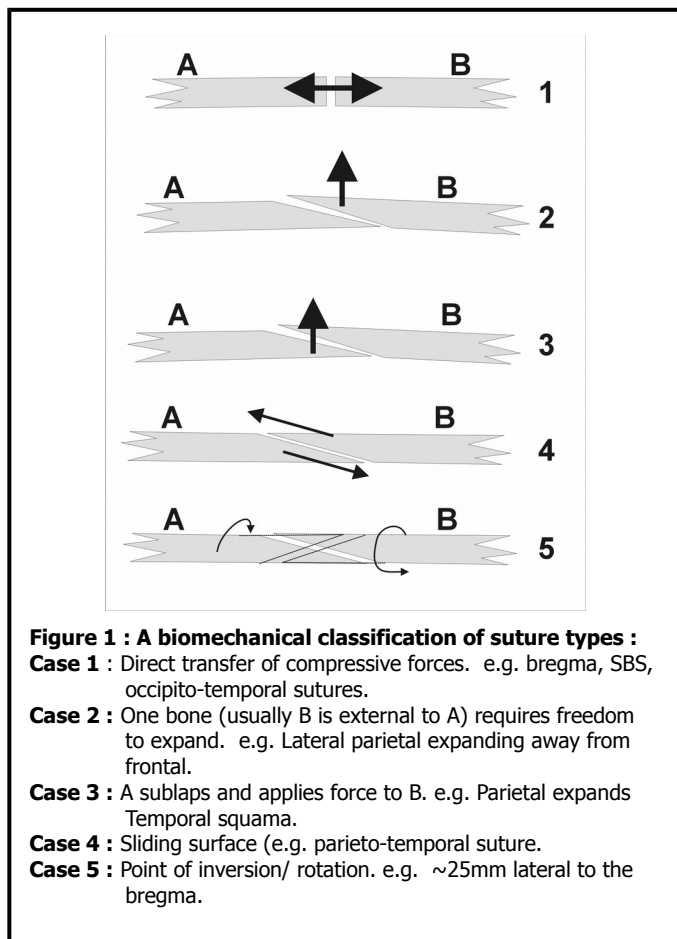
The following basic rules are derived from an analysis of cranial bone and suture *flexibility* using the principle of "*form follows function and function follows form*" and tensegrity principles.

- A. The more a bone is subject to stress (torsional, shear, compressive or tensile), the thicker it becomes. During normal physiological conditions, thick bones generally indicate a high stress load.
- B. Wherever bones have to protect vulnerable structures they become thicker or wrap around the structure in some way.
- C. Vulnerable structures are placed in locations of minimal relative bone motion.
- D. In modification of (A), wherever bones have to bend, or wherever they are not subject to large compressive forces, they become thinner. This thinning is subject to a minimum requirement imposed by the protective function of the skull.
- E. Bone *shape* is also important for strength. Flat surfaces (large radius of curvature) bend easily and domed surfaces (small radius of curvature) resist deformation. "T" or "U"-shaped sections and solid triangular masses are also particularly resistant to bending. These shapes are traditionally chosen by engineers for their rigidity.
- F. Bending is also achieved by providing lines of relative thinness or even foramina inside relatively thick or ribbed structures.
- G. Sutures can be similarly analysed to infer how much compression, shear or torsion they transmit. The thickness of the sutural face is related to the force transmitted.
- H. Tensile forces from membranes acting internally on the cranium cause compression of sutures, with some additional rotation, hinging, torsion and shear. The more complex the stresses transferred across the suture, the more complex is the suture design.
- I. Sutural faces are, on a gross level (ignoring detailed patterns), perpendicular to the forces passing through them. The direction of the face of the suture can be used to determine in which direction the bone transfers forces to and from its neighbours. On this structural basis, five simple suture classifications are proposed, shown in Figure 1.

Not just in the bones...

The above descriptions might possibly imply that sutural motions and internal-external force vectors can be large. This is not the case, as cranial sutures are synarthrotic. Regardless of the direction in which stress, strain and motion is transmitted, the suture and the bony structures on either side are held firmly –

internally by the cranial dura, and externally by the periosteum – and internal-external force vectors are likely to be minimized by adaptations of bone flexibility. Suture types 2, 3 and 4 do not transmit much (if any) compression, but rather are expressions of hinging and sliding motions contained by tensile forces within the surrounding dura and periosteum. Type 5 sutures are zones of least relative motion on a suture, and are often associated with blood vessels crossing between cranial bones.



The above principles (A to I) and suture types (1 to 5) are applied below to the major cranial bones by using them as guidelines to interpret the flexibility of a disarticulated skull.

Parietals

Each parietal bone consists of a square plate with a central dome. They are of fairly consistent thickness, with thinning at the inferior anterior corner (adjoining the sphenoid, temporals and frontal). The plain domed surface is quite difficult to deform, except in the case of a straightening of the coronal suture, which is accompanied by a slight increased doming (decreased radius of curvature) of the sagittal suture. This would imply a lateral motion of the lateral anterior corner, which is confirmed by the local type 3 suture. This flexing can also be assisted by compressive forces on the bregma and its diagonal corner. Fortunately, these two locations have type 2 sutures, confirming this distribution of forces. The widening of the anterior parietal increases the doming of the sagittal line and reduces the A-P dimension of the parietal. Compressive forces are transmitted A-

P along the line of the sagittal suture between the lambda and the bregma, both of which show type 1 sutures.

Occiput

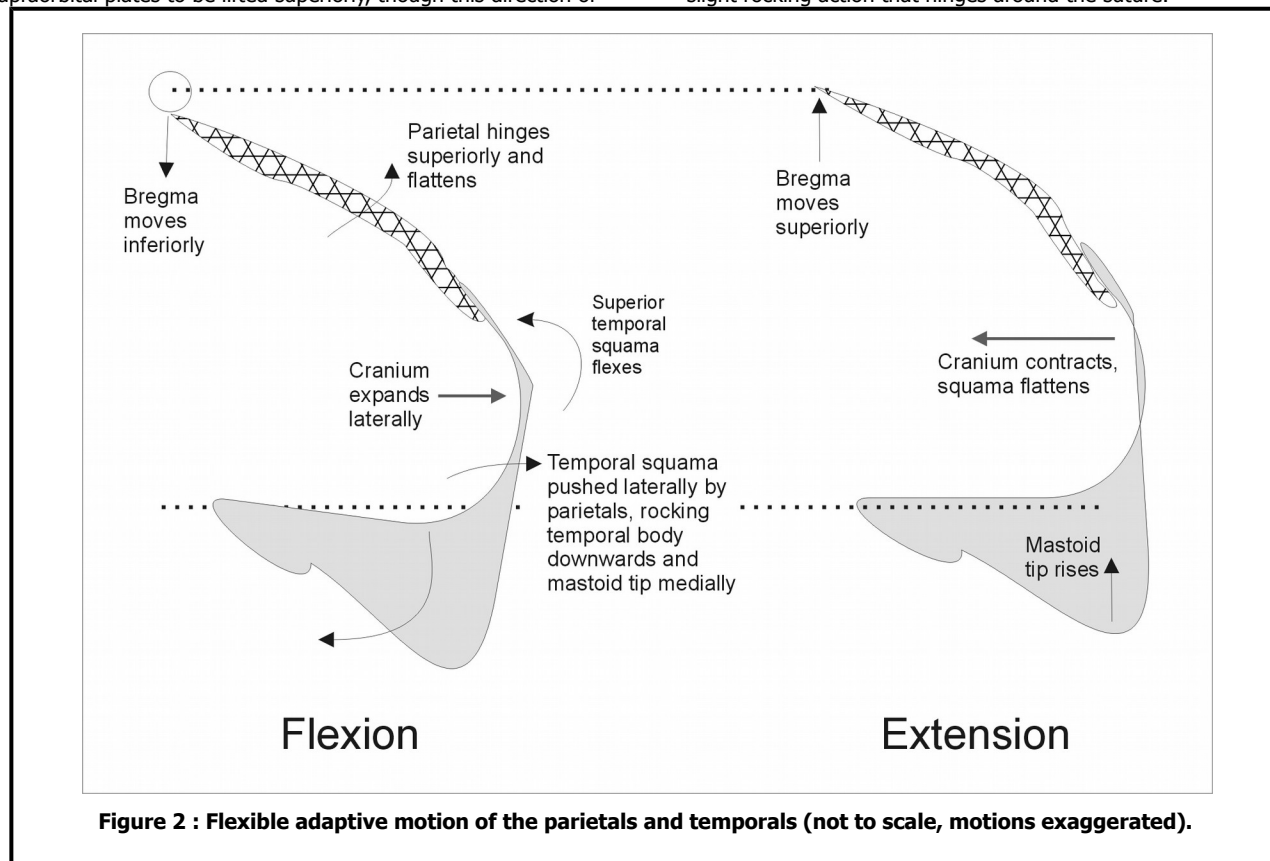
The occiput is much more solid than the parietal, having internal ribbing to anchor the tentorium and falx. This ribbing is reminiscent of moulded plastic designs that have been deliberately stiffened. The fact that the occiput is inflexible relative to the parietals is reflected in the complexity of the occipitoparietal interdigitations. The anterior occiput is even more massive, consisting of the condyles and basillum. Nevertheless, the occiput can flex along a single line of increased flexibility passing horizontally and laterally through the foramen magnum, the sigmoid sinus and the condylar and hypoglossal canals, immediately posterior to the condyles. The occiput will flex along this line (the internal angle between the squama and the basillum decreases) if the squama is directly subject to an anterior bending force *or* if the bowl of the squama is opened, both of which occur when the parietals open on Flexion. In practice, the squama moves anteriorly, since the basillum is held by the condyles. This Flexion/flexing can *only* happen, structurally, if the occiput is pulled forwards (by the dura, falx and tentorium) against the parietals and temporals. The three type 1 suture zones on the occiput are the SBS and lambda (transferring A-P compression in a sagittal plane to balance tensile forces in the falx) and the occipito-mastoid surfaces. The tentorium is stretched by lateral expansion of the parietals, and this tension pulls the occiput forward, compressing the occipito-parietal sutures; with the effect of expanding the parietals. Simultaneously, the internally directed tension of the tentorium on the parietals serves to limit this expansion. This reciprocal and synergistic relationship between tension and compression is characteristic of a tensegrity structure.

Frontal

The frontal dome is roughly the same thickness as the parietal over most of its area, with substantial thickening along the superciliary arch (eyebrows), culminating in a triangular mass of bone on the lateral aspect of the eye socket. This is proximal to the suture contacting the superior surface of the greater wings of the sphenoid. This sutural surface is internally domed and has a particularly small radius of curvature. The centrally located glabella contains the frontal sinus, and consists of a thin, complex, open box section facing inferiorly towards the ethmoid. It is reinforced posteriorly by the crista galli. The supraorbital plates are thin, but also domed; they are thickened by a series of small lumps directly above the centre of the orbit. The ethmoid notch (leading to the frontal sinus and glabella box section) provides a line of ease of motion to the frontal dome. The fact that the inferior segment of the metopic suture remains open reflects the proximity of the "weak" line of the ethmoid notch. Experientially, the frontal widens during Flexion. Classical cranial descriptions (Sutherland, 1998; Magoun, 1951) even refer to the frontal hinging around the metopic suture much as the parietals hinge around the sagittal suture. When the frontal dome widens laterally, the coronal line is pulled inferiorly, becoming more flattened, though less so than the parietals. The ethmoid notch

widens and there is a slight tendency for the ethmoid and supraorbital plates to be lifted superiorly, though this direction of

occiput and temporal, with little room for motion beyond a very slight rocking action that hinges around the suture.



motion has some ambiguity. All the sutural surfaces of the frontal bone face posteriorly or externally. The posterior-facing suture at the bregma transmits an arch of A-P compression along the sagittal line. Posterior tension of the falx on the crista galli (meeting anterior compressive forces at the bregma and glabella) is a possible mechanism for deformation of the frontal bone. This would also be confirmed by ossified animal falx structures were it assumed that cranial stress patterns were functionally similar between species.

Temporal

The temporal bone is a very solid triangular ridge connected to a very flexible squama, which accommodates parietal expansion (Figure 2). The mechanical relationship of the petrous ridge to the occiput and sphenoid is shown in Figure 3. Its sutures do not allow any vertical displacement to occur relative to either the sphenoid or occiput. However, there is a ridge along the line of the bony edge (rather than cutting across it) medial to the mastoid that interlocks with a groove in the occiput, allowing the temporal to rotate in this location relative to the occiput. This is the closest arrangement in the cranium to that of a rotating gear face; it is necessary due to the solidity of the truly rotational axis of the petrous ridge. In addition to its protective role for the inner ear, this massive ridge provides compressive and torsional strength. The interior motion of the temporal is somewhat more complex. Medially, it contains the cerebral artery, the pulsing of which is sometimes palpable. Posteriorly, there is a thick and stable sutural connection backed up by thick bone in both the

The sphenotemporal suture contains the jugular foramen, which further increases the flexibility of this line. The anterior compression from the mastoid is transferred in a wedge-like motion by a type 1 suture to the lateral SBS and inferio-posterior edge of the greater wing of the sphenoid.

Sphenoid

The sphenoid is a complex composite of many different structural properties, so the following biomechanical description is necessarily incomplete. The solid basilar portion is less than one centimetre long, and supports the posterior horns of the sella turcica. The occipito-sphenoid basillum is covered on its superior surface by the basilar venous plexus. The anterior sphenoid is a thin, pentagonal box section surrounding the sphenoid sinus, easily deformed along its diagonal axis (Figure 4). Its superior lateral angles are thickened, containing the optic foramina and the roots of the lesser wings. The lesser wings are thin and highly flexible. The inferior lateral aspects of the anterior body are also thickened, and merge into the roots of the pterygoid and greater wings. The pterygoid wings comprise a strong channel ("U") section that is also solidly anchored to the basillum. The greater wing is a complex, antero-inferiorly domed structure comprised of the middle cranial fossa and the cavernous sinus, by which it is medially filled. The superior lateral surfaces of the greater wings (which abut the frontal bone inferiorly) are triangular and "T"-shaped in section. The extreme tips are thin and flexible. The superior orbital fissure is extended by a line of accommodation passing through the foramen rotundum and

pterygoid canal. The line of the foramen ovale and foramen spinosum is similarly more flexible. These two lines work with the compliance of the anterior body to give the sphenoid the greatest flexibility of any bone in the cranium, whilst still allowing it to retain substantial A-P compressive strength. In practice, these flexible lines allow the greater wings to move anteriorly in Flexion. The anterior component of this motion is restricted by the curved surface of the middle fossa, and the tips of the wings move anteriorly and laterally in a twisting motion. This also moves the medial apex of the triangular speno-frontal suture slightly posteriorly. This compound motion parallels the detailed motion of the lower surface of the frontal. As the anterior body and greater wings flex, the sella turcica is also deformed, and the resultant "milking" action on the pituitary is a well-recognised phenomenon in CST/CO.

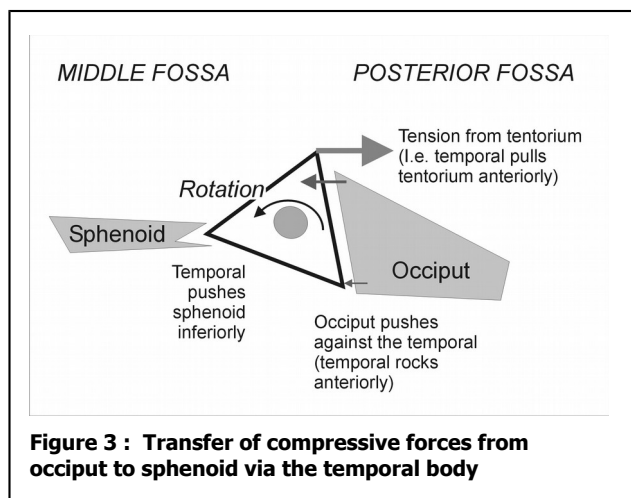


Figure 3 : Transfer of compressive forces from occiput to sphenoid via the temporal body

Motion of the Faciomaxillary Complex (FMC)

As the anterior body deforms (Figure 4), the pterygoid wings move laterally. The angle of the rostrum changes as the most anterior part of the sphenoid body flexes whilst the basilar part remains rigid. This deformation naturally results in the classically described apparent superior rotation of both vomer and ethmoid and the widening of the maxilla (Figures 4 and 5). The simultaneous widening of the anterior body also follows the ethmoid notch of the frontal.

Recent medical research on sheep (e.g., Mollanji et al., 2003; Bozanovic-Sosic, 2001) has identified that up to 70% of cerebrospinal fluid (CSF) flows out from the craniosacral system (CSS) through the cribriform plate, passing into the ethmoid and subsequently into the cervical lymphatics. This significantly revises the historical assumption in cranial and medical textbooks that all CSF is absorbed by the arachnoid villi. In this light, the arachnoid villi are secondary drainage points, and may also possibly be re-categorised as emergency relief valves for the accommodation of pressure peaks due to blows to the head. Nevertheless, there is a lot of variation and ambiguity in measurements of CSF production and reabsorption (Davson & Segal, 1996) in terms of the proportion of total flow that may be attributed to each site. The CSS may have considerable flexibility as to the proportion of CSF exiting from each drainage site.

These new findings lend importance to the rhythmic motion of the cribriform plate and ethmoid as implied by a CRI.

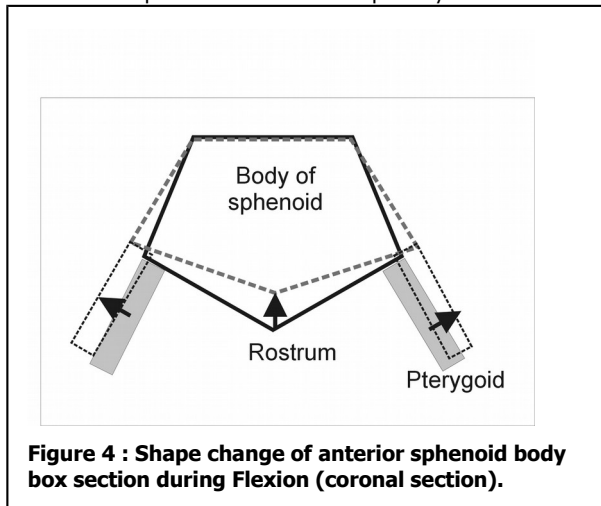


Figure 4 : Shape change of anterior sphenoid body box section during Flexion (coronal section).

F. Discussion

Considering all of the above analysis of how compression and tension are transferred within the cranium, the SBS seems to be a location of stability around which the more flexible structures appear to rotate. The phenomenon of "arcing" described by Upledger (1990) and the principle of "fulcrums" described by Sutherland (1998) and Sills (2002, 2004) give concrete examples of this in daily CST/CO practice.

The authors view is that the SBS compresses during Flexion, and that its function is to transfer A-P compressive stress through the cranial base as the vault moves, and to resist any bending, torsion or shear forces arising from motion of the cranium. This is in marked contrast to the simplified "SBS lesion" approach, which considers the SBS to be a location of motion.

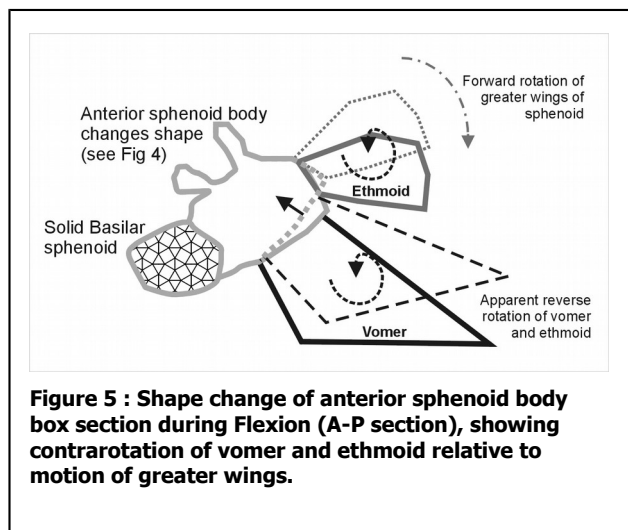
The tendency for tissues to visibly align in the direction of stress/strain is seen in the complete hierarchy of scales from alignment of actin fibres at a cellular level² to Wolff lines in bone. Arbuckle (1994, p226) described stress fibres in the tentorium and falx which give some clue as to the direction of stress they are subjected to. It is interesting that the basillum has virtually no fibres, again suggesting that there is no motion through this area; whereas the medial aspect of the cavernous sinus has a distinctly fibrous connection to the margins of the superior orbital fissure, and there is a very clear lateral band of fibres running along the line of the lesser sphenoid wings.

Stress, tension and compression patterns through sutures

It might be easy to assume from the above that cranial motion is a complex, inseparable motion of interdependent membrane and bone, with no obvious causality. However, an analysis of stress

² The importance of this to bodywork theory has been highlighted in recent research by Sultan, Stamenovic and Ingber (2004); which shows how the rheological "dashpot" effect commonly noted in cranial work is possibly caused by tensegrity structures in cells and tissues. Ingber (2003) has described a cellular model which connects the mechanical (cellular-level tensegrity) properties of human tissue to a wide range of common diseases.

direction across suture surfaces suggests that there is a very clear transfer of tension and compression through the cranial system during an F-E cycle. There must always be a tension in some fascial structures, balanced by a compression in some osseous sutures, forming a tensegrity network. Tension and compression are not in a *constant* reciprocal relationship between themselves, but rather are subject to a constantly shifting relationship within the context of the whole system (e.g. see the description of occipital motion above). This concept of alternating driving forces (instead of a whole-motion effect) is analogous to the local non-equilibrium cycles in dissipative structures, outlined in Ho (1998).



During Flexion, lateral expansion of the parietals naturally pulls the anterior and posterior sections of the cranium together, compressing all A-P facing sutures including the SBS. The forward motion of the occipital squama caused by tension in the falx is transmitted osseously through the rigid temporal body onto the SBS and flexible inferior greater wings of the sphenoid. From the wedging action of the temporal, compression is passed both anteriorly and contralaterally through the sphenoid to complete the sagittal A-P compression circle. The linking of the tentorium and falx at the straight sinus ensures that any lateral expansion is translated into an A-P tension in the falx, and any A-P tension causes a relaxation of the tentorium – a truly “reciprocal tension” arrangement.

Consequently, the temporal body *literally* pushes the inferior sphenoid anterior and slightly inferior, creating the forward motion of the faciomaxillary complex via the pterygoid wings. Of course, there may also be a circular route of tension that also pulls the pterygoid wings from deep midline structures outside the cranium (Myers, 2001).

Practical implications for treatment protocols

Very few of the ideas presented here are new. Perhaps the defining feature of this model of cranial motion is that it approaches the concept of a mobile skull from the perspective of osseous flexibility rather than from that of sutural articulation. As it is, the function and shape of the sutures is far easier to understand once their role as boundaries between mobile *and*

flexible cranial bones is fully appreciated. Similarly, the idea of a non-moving SBS is not a big conceptual step, but is more a matter of being aware how jargon might accidentally imply incorrect mechanisms that may then come to be taken at face value. This flexible model of cranial motion sits well with the recent trend towards an emphasis on an adaptive approach rather than fixed technique (Kern, 2001; Sills, 2004). Since the SBS is primarily an immobile compression joint, there is also virtue in focusing on the SBS as a location of stored energy. The author’s experience is that the SBS naturally becomes a much clearer perceptual *energetic* focus once the more complex model of motion has been assimilated and the SBS is conceptually decoupled from motion of the greater wings. Redefining the SBS as an immobile joint also places it more clearly as a Zero Balancing “Foundation Joint” as defined in Smith (1989).

It could be argued that there is no need to visualise anything more complex than simplified SBS lesion patterns (e.g. Upledger & Vredevoogd 1983) because the motions necessary to release the anterior sphenoid body are still achieved. However, Sutherland (1998) stated clearly that, “*For the perfection of skill required in cranial diagnosis and technique, it is necessary, primarily, to possess a perfect anatomical-physiological mental picture*”. Because the sphenoid is the location of greatest flexibility in the midline structures, placing great importance on its freedom of motion is in no way compromised by this revised model; however, the function of sphenoid mobilisation techniques must be viewed slightly differently.

A final word

Perhaps the most satisfying aspect of this evolved flexibility model for cranial motion is that sphenoidal motion – palpatory or otherwise – is not a necessary assumption. All that needs to be assumed is that the cranium simply changes shape. From that point, all one needs to do is ask the question – How does that happen? Everything else – all the commonly accepted cranial bone motions (with the obvious exception of SBS hinging) – come about as a logical conclusion from the fact of a semi-rigid structure accommodating motion. As has been stated previously, ossified relic sutures will also act as lines of preferential folding, so life-long retention of membranous sutures is not a necessary prerequisite of cranial motion. This is an unexpected and welcome relief in that it removes a lot of hoops and hurdles from the process of technical (medical) justification of CST/CO techniques while answering some of the valid questions raised by Hartman and Norton (2002). From this point, a simple and repeatable demonstration of cranial dimension change (e.g. as used by Moskalenko et al., 1999) would constitute a very good proof of the functionality of the sutures and of the *potential* usefulness of the standard CST/CO techniques.

G. Conclusions

It is possible to explain the motion of cranial bones by use of a model that presupposes flexibility of bones, a mechanical structure based on tensegrity principles, and with an overriding assumption that biological structures self-optimize. This evolved model applies the principle of “form follows function and function follows form” to bone thickness in addition to suture patterns. Its conclusions – with regard to cranial work – include the possibility that the SBS is an essentially compressive-decompressive joint rather than a primary source of motion.

This flexible bone model successfully accounts for recognised palpated patterns of cranial bone motion in a logically consistent manner and resolves commonly glossed over questions about different aspects of cranial motion in the vicinity of the SBS. In particular, it fully accounts for the apparent “quadruple-gear” motion of the occiput-sphenoid-vomer/ethmoid complex. The apparent motion of the SBS is probably an arcing phenomenon in the rest of the cranium around the relatively immobile basilium. Palpated sphenoid motion would therefore be a result of deformation of the anterior body and flexing of the greater wings of the sphenoid. This mobility of the sphenoid is made possible by the presence of the sphenoidal sinus and orbital fissures. Much of the above analysis is based on simple playing with a disarticulated skull.

H. Acknowledgements

I am grateful to Mij Ferret for his helpful and apposite (as always!) comments, to James Norton for constructive dialogue on this model in its early stages of development, and to Keith Farvis and Bill Ferguson for their support and for putting it into practice. It almost goes without saying that my CST teachers have contributed enormously to this by providing a structure whilst encouraging me to find my own way. I would particularly like to thank Zhixing Wang, who helped to release the creative energy which produced these ideas.

I. Addenda to published version

The ideas in here have been refined since they were originally written in 2003 – for an updated version see

<http://www.hummingbird-one.co.uk/pdf/SOJ2015.pdf>

References

- Bozanovic-Sosic R, Mollanji R & Johnston MG (2001) Spinal and cranial contributions to total cerebrospinal fluid transport. *AJP Reg Int Comp Physiol.* 281:3 Sep R909-16
- Adams T, Heisey RS, Smith MC, & Briner BJ (1992) Parietal bone mobility in the anesthetized cat. *Journal of the American Osteopathic Association* 92: 599-624
- Arbuckle BE (1994) *The Selected Writings of Beryl E. Arbuckle. Revised Edition*, Publ. American Academy of Osteopathy, Indianapolis USA
- Byron CD, Borke J, Yu J, Pashley D, Wingard CJ, Hamrick M (2004) Effects of increased muscle mass on mouse sagittal suture morphology and mechanics. *The Anatomical Record.* Jul;279A(1):676-84
- CSTA (2002) *Standards of Practitioner Competencies*. The Craniosacral Therapy Association (UK), Monomark House, 27 Old Gloucester Street, LONDON, WC1N 3XX
- Davson H & Segal MB (1996) *Physiology of the CSF and blood-brain barriers*. Publ. CRC Press
- Hartman SE & Norton JM (2002) Interexaminer Reliability in Cranial Osteopathy. *The Scientific Review of Alternative Medicine* 6(1), 23-35
- Ho, Mae-Wan (1998) *The Rainbow and the Worm - the physics of organisms*. World Scientific Publishing Co., Singapore
- Ingber DE (1998) *The architecture of life*. *Scientific American*, January 48-57
- Ingber DE (2003) Mechanobiology and diseases of mechanotransduction. *Annals of Medicine*.35(8), pp 564-77
- Jaslow CR (1990) Mechanical properties of cranial sutures. *Journal of Biomechanics*; 4:313-321
- Kern M. (2001) *Wisdom in the Body – the craniosacral approach to essential health*. Publ. Thorsons, London
- Magoun HI (1951) *Osteopathy in the Cranial Field*, 1st Edition. Publ. The Sutherland Cranial Teaching Foundation Inc., Fort Worth, Texas USA.
- Milne H (1995) *The Heart of Listening Listening – a visionary approach to craniosacral work*. Vols I and II. Publ. North Atlantic Books, Berkeley, California USA
- Mollanji R, Bozanovic-Sosic R, Zakharov A, Makarian L & Johnston MG (2003) Blocking cerebrospinal fluid absorption through the cribriform plate increases resting intracranial pressure. *American Journal of Physiology (AJP) Reg Int Comp Physiol* 282:6(June) R1593-9
- Moskalenko YuE, Kravchenko TI, Gaidar BV, Vainshtein GB, Semernya VN, Maiorova NF & Mitrofanov VF. (1999) Periodic Mobility of Cranial Bones in Humans. *Human Physiology* 25(1):51-58 (English version, ISSN 0362-1197, <http://maik.rssi.ru/>)
- Myers TW. (2001) *Anatomy Trains*. Publ. Churchill Livingstone
- Nelson KE, Sergueef N, Lipinski CM, Chapman AR, Glonek T. (2001) Cranial rhythmic impulse related to the Traube-Hering-Mayer oscillation: comparing laser-Doppler flowmetry and palpation. *Journal of the American Osteopathic Association*, 101(3): 163-73
- Ogle RC, Tholpady SS, McGlynn KA & Ogle RA. Regulation of cranial suture morphogenesis. (2004) *Cells Tissues Organs* 176(1-3):54-66. Related Articles, Links
- Oleski SL, Smith GH & Crow WT. (2002) Radiographic Evidence of Cranial Bone Mobility. *Cranio: The Journal of Craniomandibular Practice (January)*, V20N1, pp 34 ff
- Sergueef N, Nelson KE & Glonek T (2002) The effect of cranial manipulation on the Traube-Hering-Mayer oscillation as measured by laser-Doppler flowmetry. *Alternative Therapies in Health and Medicine*. 2002 Nov-Dec;8(6):74-6
- Sills F (2002) *Craniosacral Biodynamics I* Publ. North Atlantic Books , Berkeley, California USA
- Sills F (2004) *Craniosacral Biodynamics II The primal midline and the organisation of the body* Publ. North Atlantic Books , Berkeley, California USA
- Singer R. (1953) Estimation of age from cranial suture closure: Report on its unreliability. *Journal of Forensic Medicine* (1):52-59
- Smith FF (1989) *Inner Bridges: Guide to Energy Movement and Body Structure*. Publ. Humanics Publishing Group, Florida USA
- Steenvoorden GP, van de Velde JP, Prah-Andersen B (1990) The effect of duration and magnitude of tensile mechanical forces on sutural tissue in vivo. *European Journal of Orthodontics*. Aug;12(3):330-9
- Sultan C, Stamenovic D, Ingber DE. (2004) A computational tensegrity model predicts dynamic rheological behaviors in living cells. *Annals of Biomedical Engineering*. 32(4), pp 520-530
- Sutherland WG (1939) *The Cranial Bowl*. Free Press. Reprinted by The Cranial Academy (1986)
- Sutherland WG (1998) *Contributions of Thought – The collected writings of William Garner Sutherland DO*, 2nd Edition. Publ. The Sutherland Cranial Teaching Foundation Inc., Fort Worth, Texas USA.
- Upledger JE & Vredevoogd JD (1983) *Craniosacral Therapy I*. Publ. UI Publishing, Palm Beach Gardens, Florida USA
- Upledger JE (1987) *Craniosacral Therapy II : Beyond the Dura*. Publ. UI Publishing, Palm Beach Gardens, Florida USA
- Upledger JE (1990) *SomatoEmotional Release and Beyond*. Publ. UI Publishing, Palm Beach Gardens, Florida USA
- Upledger JE (1995) *Research and observations that support the existence of a craniosacral system*. Monograph, Publ. UI Publishing, Palm Beach Gardens, Florida USA. Also as <http://www.upledger.com/news/p-mon.htm>